

Transanal resection of rectal perineuroma: A rare tumor in an unusual location

Carolina Riscanevo-Bobadilla¹, Ronel Eduardo Barbosa², Diego Valbuena², Lucy Bravo³

Fundación Universitaria Sanitas¹ and Clínica Universitaria Colombia, Bogotá¹, Colombia

¹ Resident, Department of General Surgery¹

² Coloproctologist, Department of General Surgery²

³ Pathologist, Pathology Laboratory³

ABSTRACT

Colorectal perineuromas are benign mesenchymal tumors with an incidence of 0.1 to 1.4%. Rarely, a malignant serrated variant may occur. They usually present as sessile polyps or subepithelial tumors. Endoscopic features are nonspecific, and diagnosis is based on histological and immunohistochemical analysis.

We present the case of a 52-year-old patient who presented with intermittent episodes of painless rectal bleeding. Colonoscopy showed a neoplastic-appearing, protruding, and ulcerated lesion in the lower rectum, with biopsies negative for malignancy. Endorectal ultrasound showed an intact rectal muscularis propria and absence of lymphadenopathy. A second colonoscopy to obtain additional material led to a diagnosis of lower rectal perineuroma, which revealed an ill-defined proliferation of spindle cells without atypia, confined to the mucosa, with positive immunohistochemistry for EMA, GLUT-1, and Claudin-1. A transanal full-thickness resection (TAMIS) was performed, and histopathology confirmed the diagnosis and the absence of malignancy, showing lesion-free resection margins and negative lymph nodes.

Keywords: Rectal Perineuroma; TAMIS; GLUT-1; EMA; Claudin-1

INTRODUCTION

Perineuromas are benign mesenchymal tumors originating from the sheath of peripheral nerves; however, extraneural presentations in soft tissues have been reported.¹ In 70% of cases, it is located in the rectosigmoid colon,⁴ while it is exceptional in the small intestine and stomach.⁵

The estimated incidence ranges from 0.1 to 1.4%, and the mean age of presentation at diagnosis is 60 (35-87) years.³

It is identified incidentally during endoscopic studies as a sessile, subepithelial lesion,⁴ and its definitive diagnosis is made by histopathological study and complementary immunohistochemistry, which demonstrate its perineural differentiation, with antibodies such as GLUT1, Claudin-1, and EMA.⁵

Differential diagnoses such as polypoid ganglioneuroma, mucosal Schwann cell hamartoma, neurofibroma, gastrointestinal stromal tumor (GIST), and inflammatory fibroid tumor should be ruled out,^{5,6} by performing extension studies to evaluate their origin, biological behavior, clinical characteristics, and natural history.

Además de establecer las bases inmunohistoquímicas de los perineuromas de origen gastrointestinal para confirmar el diagnóstico, es fundamental determinar su pronóstico, su potencial de regeneración y la necesidad de seguimiento endoscópico.

Presentamos un caso de perineuroma de recto con crecimiento polipoide tratado mediante resección transanal, sin recurrencia tras un año de seguimiento endoscópico.

CASE

A 52-year-old male with chronic constipation had experienced intermittent episodes of painless rectal bleeding for the past three months. He reported no weight loss, change in bowel habits, or family history of colorectal cancer. A colonoscopy revealed an elevated, ulcerated, infiltrative-appearing lesion with a depressed center on the inferior Houston valve, involving approximately 50% of the rectal circumference. Biopsies were taken. No synchronous lesions were identified (Fig. 1A).

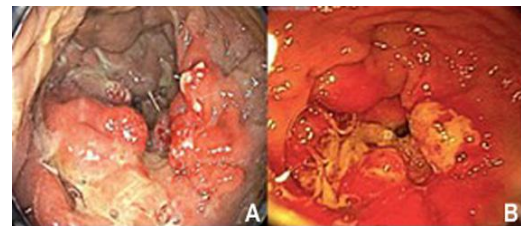

Figure 1. Colonoscopy. A sessile, elevated lesion with an infiltrative neoplastic appearance and central depression is observed in the lower rectum, 4 cm from the dentate line and affecting the first Houston valve. It involves 50% of the rectal circumference and extends longitudinally 3 cm proximally.

Histopathological examination revealed ulcerated rectal mucosa with granulation tissue and reactive epithelial changes, with no evidence of malignancy.

Given the lesion's endoscopic findings, which suggest a tumor, and the patient's age, additional studies were performed. Endorectal ultrasound revealed thickening of the rectal mucosal folds without involvement of the muscularis propria or mesorectal lymphadenopathy (Fig. 2).

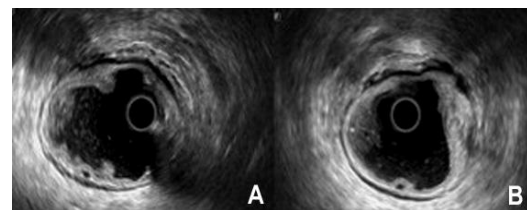


Figure 2. Endorectal ultrasound. Thickening of the rectal folds with ulceration affecting the mucosa and submucosa, sparing the muscularis propria. Absence of lymphadenopathy in the mesorectum.

The authors declare no conflicts of interest. **Angie Carolina:** caroriscanevo@unisanitas.edu.co
Received: 09-10-2024. Accepted: 21-04-2025

Carolina Riscanevo-Bobadilla [ORCID: 0000-0002-3224-5729](https://orcid.org/0000-0002-3224-5729), Ronel Eduardo Barbosa [ORCID: 0000-0001-5089-0820](https://orcid.org/0000-0001-5089-0820), Diego Valbuena [ORCID: 0000-0003-4212-9884](https://orcid.org/0000-0003-4212-9884), Lucy Bravo [ORCID: 0000-0002-3085-7350](https://orcid.org/0000-0002-3085-7350)

Histopathological analysis confirmed the absence of malignancy and showed lesion-free resection margins. Immunohistochemical testing confirmed the diagnosis, highlighting positivity for EMA and GLUT-1 and negativity for BRAF (Fig. 4).

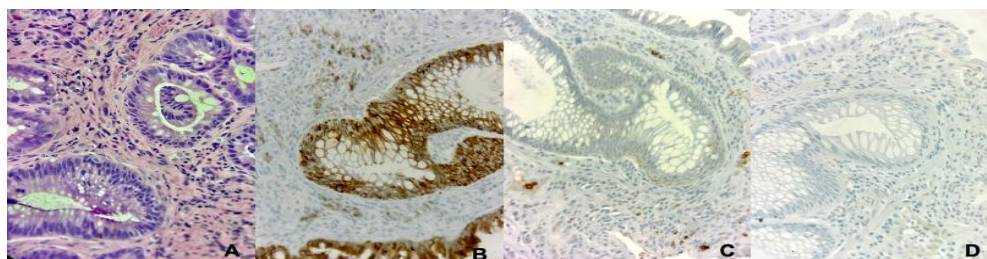


Figure 4. Histological features of perineuroma of the rectum. **A.** Distorted crypts, characterized by their focal lamellar and whorled structure. The cells are spindle-shaped, with ovoid or thin nuclei and pale cytoplasm, in a thin, fibrillar stroma. H&E. **B.** Immunohistochemistry (IHC) for epithelial membrane antigen (EMA). **C.** IHC for glucose transporter-1 (GLUT 1). **D.** IHC for collagen IV.

DISCUSSION

Colorectal perineuromas are tumors that originate from mesenchymal stromal cells that express perineural markers, usually located in the mucosa or submucosa.¹ They were first described in 2004 by Eslami-Varzaneh et al.² as a benign fibroblastic polyp.

Gastrointestinal perineuromas, also known as fibroblastic polyps, are benign, usually asymptomatic mucosal lesions discovered incidentally during endoscopic studies in symptomatic patients and during colon cancer screening programs. Endoscopic findings are subject to variation. Endorectal ultrasound is a useful diagnostic tool for identifying subepithelial tumors, though precise identification can be difficult in some cases.^{3,4}

Histologically, perineuromas are characterized by the proliferation of spindle cells within the lamina propria, without cytological atypia, mitosis, or necrosis. To confirm the diagnosis, perineural differentiation must be confirmed by immunohistochemical reactions with antibodies such as claudin-1 (a protein of the integral transmembrane protein family, with a structural and functional role in tight junctions), GLUT-1 (a member of a family of human glucose transporter proteins), and EMA (an epithelial membrane antigen that can be focally and weakly expressed). Claudin-1 and GLUT-1 exhibit high sensitivity and relative specificity as markers of the perineurium, facilitating its differentiation from other mesenchymal cells.³ The expression of CD34 is positive in approximately 50% of cases, while staining for S100 and GFAP is negative.^{5,6}

Perineuromas are considered benign neoplasms, with a low incidence of recurrence. There is no convincing evidence on the rate of malignant transformation.⁷ Although malignant perineuroma has the potential to metastasize, its behavior is generally less aggressive than that of other tumors.

The differential diagnosis of perineuromas includes ganglioneuromas, neurofibromas, leiomyomas of the muscularis mucosa, and benign fibroblastic polyps.⁸ Variants of the epithelial components of serrated fibroblastic polyps have been identified that can display BRAF mutations, which can subsequently trigger fibroblast differentiation and proliferation.⁵

The optimal frequency of follow-up for patients with perineuroma should be established. Continuous postpolypectomy surveillance, with intervals similar to those indicated for serrated polyps, has been proposed due to the malignant potential of BRAF-positive serrated variants.

The recommended treatment involves the complete excision of the tumor, followed by histopathological analysis to establish an accurate diagnosis.⁹⁻¹¹ A range of surgical

The patient was followed up at one week, six months, and one year. During follow-up in the first 12 months, no endoscopic, radiological, or clinical evidence of local recurrence or metachronous lesions was found.

procedures exist that allow for the resection of rectal lesions with minimal surgical trauma. These include transanal endoscopic microsurgery (TEM) and transanal minimally invasive surgery (TAMIS). These surgical procedures are indicated for benign rectal neoplasms or T1 cancers with histologically favorable characteristics, in which the risk of lymph node metastasis is low.^{12,13} Prior to performing the full-thickness resection, a 1-centimeter margin should be marked around the entire lesion. The defect can be closed transversely to avoid narrowing the rectal lumen, as was done in the present case. However, closure is not imperative when the resection is extraperitoneal.

Before performing the full-thickness resection, a 1-centimeter margin should be marked around the entire lesion. The defect can be closed transversely to avoid narrowing the rectal lumen, as was done in the present case. However, closure is not imperative when the resection is extraperitoneal.^{14,15}

CONCLUSIONS

Colorectal perineuromas represent a rare form of benign mucosal lesions, and their histopathological characterization is paramount for effective endoscopic surveillance, as malignant variants are infrequent. Staining for EMA, GLUT-1, and Claudin-1 is a useful diagnostic tool in distinguishing perineuromas from other spindle-shaped neoplasms of the gastrointestinal tract.

The most effective treatment approach is complete excision. Minimally invasive transanal surgery is a safe and effective method for the resection of carefully selected benign and early malignant neoplasms of the mid and distal rectum.

REFERENCES

- Otani T, Hatakeyama K, Ohtani E, Nakayama S, Fujimoto T, Ohbayashi C. A Colonic Perineuroma. *Clin Med Insights Pathol.* 2018;11:117955718815918.
- Eslami-Varzaneh F, Washington K, Robert ME, Kashgarian M, Goldblum JR, Jain D. Benign Fibroblastic Polyps of the Colon: A Histologic, Immunohistochemical, and Ultrastructural Study. *Am J Surg Pathol.* 2004;28(3):374-8.
- van Wyk AC, van Zyl H, Rigby J. Colonic Perineuroma (Benign Fibroblastic Polyp): Case Report and Review of the Literature. *Diagn Pathol.* 2018;13(1):16.
- Jama GM, Evans M, Fazal MW, Singh-Ranger D. Perineuroma of the Sigmoid Colon. *BMJ Case Rep.* 2018;2018:bcr2018227170.
- van Wyk AC, van Zyl H, Rigby J. Colonic perineuroma (benign fibroblastic polyp): case report and review of the literature. *Diagn Pathol.* 2018;13(1):16.
- Kolli S, Gujjula S, Ona MA. Colonic Perineuroma's Malignant Proximity to Serrated Colonic Polyps. *Cureus.* 2019;11(6):e4815.

7. Mocellin, S. *Soft Tissue Tumors: A Practical and Comprehensive Guide to Sarcomas and Benign Neoplasms*. 2021. Cham: Springer International Publishing, pp. 639-640.
8. Álvarez Cuenllas B, Pisabarrós Blanco C, Vaquero Ayala L, García Alvarado M, Álvarez Cañas C, Díez Rodríguez R, et al. Características clínico-patológicas de los perineuromas colónicos. *Gastroenterol Hepatol*. 2012;35(10):700-3.
9. Motta F, Spadola S, Bosco A, Aprile G, Piombino E, Magro G. Perineuroma of the Colon: An Uncommon Tumor with an Unusual Location. Report of a Case and Review of the Literature. *Pathologica*. 2018;110(2):111-15.
10. Grech P, Schofield JB. Spindle Cell Proliferations of the Sigmoid Colon, Rectum and Anus: A Review with Emphasis on Perineuroma. *Histopathology*. 2020;76(3):342-53.
11. Abrari, A, Hasan N, Akhtar K. Primary Rectal Perineuroma: A Rare Incidental Finding. *Oncology J India*. 2024;8(1):16-9.
12. Jama GM, Evans M, Fazal MW, Singh-Ranger D. Perineuroma of the Sigmoid Colon. *BMJ Case Rep*. 2018;2018:bcr2018227170.
13. Kamionkowski S, Issak A, Zhang C, Wang Y, Kyprianou A. A Solitary Sigmoid Perineuroma in an Otherwise Healthy 30-Year-Old Male. *Cureus*. 2021;13(5):e15104.
14. deBeche-Adams T, Hassan I, Haggerty S, Stefanidis D. Transanal Minimally Invasive Surgery (TAMIS): a clinical spotlight review. *Surg Endosc*. 2017;31(10):3791-800.
15. Cowan ML, Silveira ML. Management of Rectal Polyps. *Clin Colon Rectal Surg*. 2016;29(4):315-20.