

# Enterobius vermicularis parasitosis as a cause of acute appendicitis

Andrés Felipe Escudero-Sepúlveda, Emilia Victoria Alzuri, Sergio Campos, Laura Beatriz Lapertosa

Hospital Interzonal General de Agudos Luisa Cravenna de Gandulfo, Lomas de Zamora, Provincia de Buenos Aires, Argentina.

## ABSTRACT

Acute appendicitis is the most common cause of acute abdomen and surgery worldwide. The prevalence of *Enterobius vermicularis* infestation as a cause of acute appendicitis in the US is approximately 2%. This article presents a case of acute appendicitis complicated with perforation and localized peritonitis associated with the presence of a parasite that later studies classified as *Enterobius vermicularis*.

**Key words:** appendicitis, *Enterobius vermicularis*, enterobiasis, intestinal parasitosis, treatment

## INTRODUCTION

Acute appendicitis is the most common cause of acute abdomen and surgery worldwide.<sup>1,2</sup> The prevalence of *Enterobius vermicularis* infections as a cause of acute appendicitis in the US is approximately 2%.<sup>3</sup> The presence of parasites in pathological samples reaches 0.5%.<sup>1</sup> However, it is worth clarifying that the main cause of acute appendicitis in adults is obstruction, fecal impaction and fecaliths.<sup>4</sup> The infestation caused by *Enterobius vermicularis*, also called *Oxiurus vermicularis*, is called enterobiasis.<sup>5</sup> Parasites associated with appendiceal symptoms are observed in 0.05-3% of cases, with the cecal appendix found inflamed on certain occasions.<sup>2</sup> The presence of the parasite in the pathological sample is around 1.5-4.2% (2). The transmission of enterobiasis is mainly fecal-oral, the life cycle is 2 to 4 weeks, and humans are known as the only reservoir.<sup>2,3</sup> It is transmitted by contamination through fomites, bedding, utensils and others. Re-infestation occurs due to new ingestion of eggs (auto-infestation) or acquisition from other sources.<sup>5</sup>

Appendicitis due to *Enterobius vermicularis* is mainly asymptomatic and when it presents clinical manifestations, anal and/or bulbar pruritus is characteristic,<sup>1</sup> as well as gastrointestinal and anxiety disorders, mainly bruxism.<sup>5</sup> Some studies report that up to 54% of patients refer abdominal pain in their medical history.<sup>1</sup>

The presence of the parasite in the appendiceal lumen can cause what is called appendiceal colic, whether or not associated with acute inflammation.<sup>1,6</sup> The mature worm *Enterobius vermicularis* lives in the proximal ascending colon, cecum, appendix and terminal ileum and is the most common parasite found in the cecal appendix.<sup>7</sup>

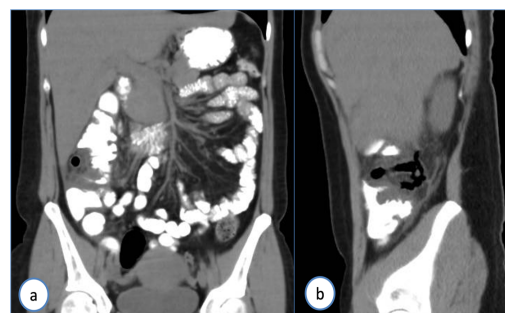
The diagnosis is made with serological studies and stool examination in suspected cases. Stool examinations are very simple and easy to perform in laboratories.<sup>8</sup>

In cases of suspected appendicitis, ultrasound and computed tomography (CT) have been shown to be beneficial, with

reported sensitivities of 95% and 96%, respectively, and a negative predictive value of 99%.<sup>7</sup>

## CASE

A 40-year-old female patient, dog groomer by profession, with two school-age children, attended the emergency department with a 2-day history of abdominal pain, predominantly in the epigastrium and right flank, associated with nausea and vomiting. She reported consumption of self-medicated analgesics and antispasmodics and denied other symptoms. On physical examination, she had pain on palpation in the epigastrium and right flank, with guarding and rebound tenderness. Laboratory tests showed: hemoglobin 14g/dl, hematocrit 39%, WBC 27,200/mm<sup>3</sup>, CRP 91mg/dl, BUN 23mg/dl, creatinine 0.7mg/dl. CT scan of the abdomen and pelvis reported altered fat in the right iliac fossa and right flank, thickening of the posterior aspect of the ascending colon, compatible with retrocecal appendicitis (Fig. 1).

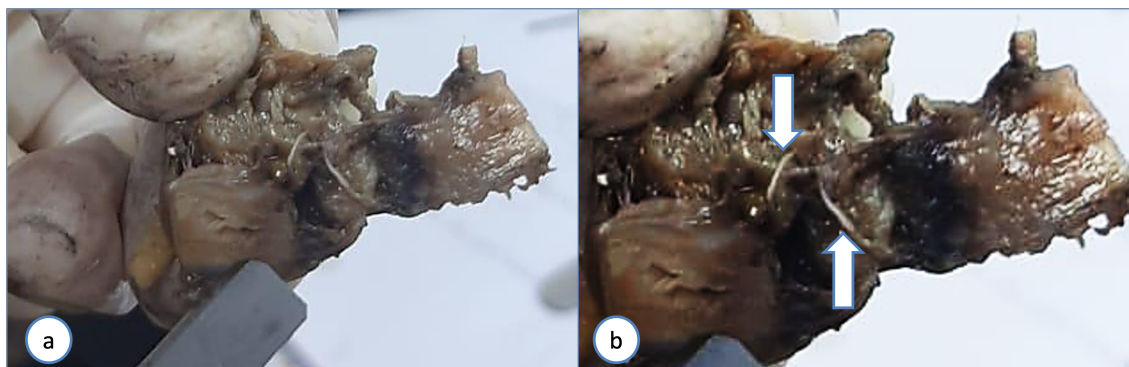


**Figure 1.** Computed tomography reported alteration of fat in the right iliac fossa with extension to the ipsilateral flank. Thickening of the posterior aspect of the ascending colon, compatible with a retrocecal appendiceal process.

Based on the clinical and imaging findings, exploratory laparotomy was indicated, finding purulent fluid in the right upper quadrant and an important retrocecal subserous ce-coappendicular inflammatory process with acute gangrenous and perforated appendicitis. When performing the appendectomy, the release of live parasites was observed in the ostium of the resected appendix (Fig. 2).

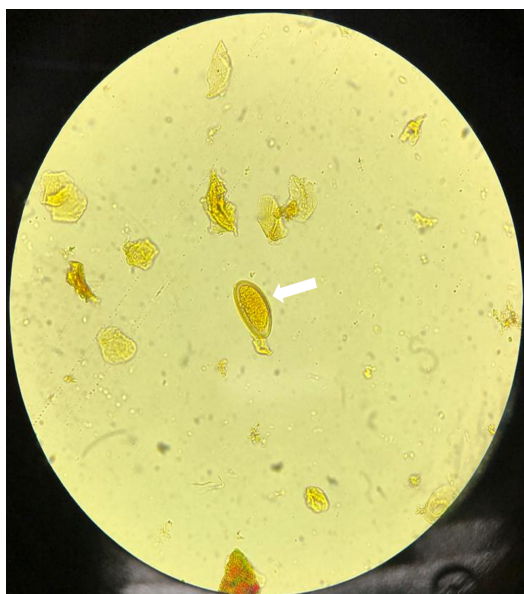The author declare no conflicts of interest. **Andrés Felipe Escudero Sepúlveda**  
Received: August 25, 2021. Accepted: March 18, 2024.

Andrés Felipe Escudero Sepúlveda: <https://orcid.org/0000-0002-4246-5469>



**Figure 2.** a. Perforated gangrenous appendix with the presence of *Enterobius vermicularis* in its lumen. b. Contrast adjustment of the image shows two parasites in the appendiceal lumen (white arrows).

Histopathology reported acute gangrenous perforated appendicitis with the presence of *Enterobius vermicularis* and eggs in the lumen, confirmed through the Graham test (Figs. 3 and 4). The patient had an uneventful recovery. Oral treatment with albendazole 400 mg in a single dose was indicated for the patient and her family.

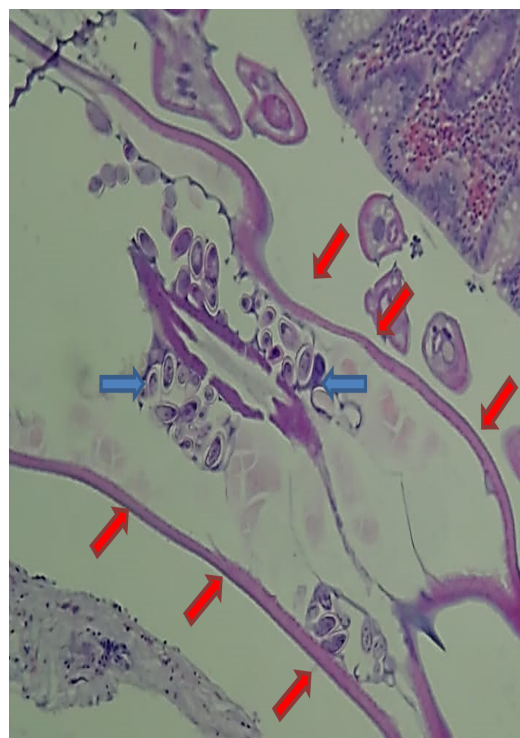


**Figure 3.** Graham test. An *Enterobius vermicularis* egg is observed (white arrow).

## DISCUSSION

The most common parasitic infection worldwide is that caused by *Enterobius vermicularis* which affects around one billion people, mainly children and young people. Its distribution is universal, affecting all age groups and socioeconomic levels,<sup>1,5,7</sup> being more prevalent in developing and tropical countries.<sup>8,9</sup>

When the parasite obstructs the appendiceal lumen, it causes irritation of the mucosa, inflammation and bacterial overgrowth, which would trigger acute appendicitis.<sup>1,4,6,9</sup> However, other authors report that chronic manifestations are found in *Enterobius vermicularis* infection, so the exact pathophysiological mechanism remains controversial.<sup>10</sup> Infections of the gastrointestinal system due to parasitic and protozoal infestations have different incidence throughout the world.<sup>9</sup> In a meta-analysis published in 2020, out of 59



**Figure 4.** *Enterobius vermicularis* parasite (red arrows) surrounded by eggs (blue arrows).

studies with 103,195 anatomical specimens, a prevalence of *Enterobius vermicularis* of 4% (95% CI, 2-6%) was found.<sup>3</sup> Another meta-analysis published by Zakaria et al, which includes 51,815 pathological specimens, reports the presence of this parasite in 4.45% of cases of acute appendicitis. A study carried out in Peru in 2011, where a total of 21,038 surgical resection specimens were analyzed, demonstrated the presence of *Enterobius vermicularis* in 1.53% of cases, with a higher prevalence in young women.<sup>1</sup> Another Peruvian study published in 2013 reported an incidence of 5.4% in 398 cases.

In our country, in 2017 an incidence of 3.25% out of 2,000 pathological specimens was reported.<sup>5</sup> What is striking about this study is that the appendix was normal, demonstrating that the parasite itself is not a causal agent of acute appendicitis, but rather an adjuvant factor.

In Canada, an incidence of less than 0.6% of cases of acute appendicitis is reported.<sup>1</sup> Regarding the distribution according to socioeconomic level, we found that infection by this

parasitosis in countries with high, middle-high, middle-low and low income levels was 3% (95% CI: 2-4), 4% (95% CI: 1-10%), 8% (95% CI: 1-21%) and 1%, (95% CI: 1-3), respectively.<sup>3</sup>

The presence of *Enterobius vermicularis* seems to favor the formation of fecaliths and bacterial proliferation in the appendiceal lumen, acting as an etiopathogenic mechanism of acute appendicitis.<sup>5,6</sup>

Another controversial factor is the presence or invasion of parasite eggs in the appendix,<sup>3,8</sup> with an incidence of 1.3% in a study carried out in 2015 in Pakistan in 2,956 pathological specimens.

As a complement to appendectomy, benzimidazole anthelmintics such as albendazole are used in the treatment. The medication must also be administered to the family members since they can serve as a reservoir, favoring reinfections.<sup>1</sup> The dose is 400 mg, repeated after 2 weeks.<sup>11</sup>

## CONCLUSION

Acute appendicitis associated with *Enterobius vermicularis* infestation accounts for about 2% of all cases. Differences are reported in the prevalence of parasitosis in different environments, being the main cause of abdominal pain. Treatment requires appendectomy associated with antiparasitic medication for both the patient and her family to prevent reinfections.

## REFERENCES

1. Tapia EO, Muñoz CC. Oxiuriasis apendicular: estudio de prevalencia y descripción clínico-morfológica. *Rev Chil Cir.* 2011;63(6):599-603.
2. Echazarreta-Gallego E, Córdoba-Díaz de Laspra E, Mejía-Urbaz E, Hernández-Arzo A, Sánchez-Blasco L, Elia-Guedea M. Apendicitis y parásitos: a propósito de 2 casos. *Rev Chil Cir.* 2016;68(5):373-75.
3. Taghipour A, Olfatifar M, Javanmard E, Norouzi M, Mirjalali H, Zali MR. The neglected role of *Enterobius vermicularis* in appendicitis: A systematic review and metaanalysis. *PLoS One.* 2020;15(4):1-15.
4. Vilela Desposorio CD, Cusma Quintana TNC. Type of acute appendicitis. *Rev Gastroenterol Peru.* 2015;35(6):31-7.
5. Spitale LS, Pizzi RD, Tomas A, Paez Rearte MG, Pizzi HL. Rol del enteroparásito *Enterobius vermicularis* en la apendicitis cecal. *Rev Fac Cien Med Univ Nac Cordoba.* 2017;74(3):277-80.
6. Akkapulu N, Abdullazade S. Is *Enterobius vermicularis* infestation associated with acute appendicitis? *Eur J Trauma Emerg Surg.* 2016;42(4):465-70.
7. Gialamas E, Papavramidis T, Michalopoulos N, Karayannopoulou G, Cheva A, Vasilaki O, et al. *Enterobius vermicularis*: a rare cause of appendicitis. *Turkiye Parazit Derg.* 2012;36(1):37-40.
8. Yabanoğlu H, Aytaç HÖ, Türk E, Karagülle E, Calişkan K, Belli S, et al. Parasitic infections of the appendix as a cause of appendectomy in adult patients. *Turkiye Parazit Derg.* 2014;38(1):12-6.
9. Altun E, Avci V, Azatçam M. Parasitic infestation in appendicitis. A retrospective analysis of 660 patients and brief literature review. *Saudi Med J.* 2017;38(3):314-18.
10. Ahmed MU me., Bilal M, Anis K, Khan AM ahmoo., Fatima K, Ahmed I, et al. The frequency of *Enterobius vermicularis* infections in patients diagnosed with acute appendicitis in pakistan. *Glob J Health Sci.* 2015;7(5):196-201.
11. Habashi R, Patrick Lisi M. Acute appendicitis and *Enterobius vermicularis* infestation. *CMAJ.* 2019;191(17):E477.